INTRODUCTION

What is Metastasis ?

It is process of development of secondary tumors discontinuous with the primary tumor in remote tissues.

Prevention of Metastasis would extend life span of patient

Routes/pathways of metastasis

1. Lymphatic route
2. Haematogenous route
3. Seeding within body cavities
4. Unusual route

(VG by coitus, surgical procedures)

NEOPLASIA

- **Routes of invasion**-

1. **Infiltration into tissue spaces-**

Intracellular invasion- muscle fibres-penetrating sarcolemmal sheath.

2. **Lymphatic spread –**

a) by embolism –

b) by Permeation –

The tumor cells extend along the lymphatics by growing along the endothelium and lumen known as permeation.

NEOPLASIA

- **SPREAD OF TUMORS:-**

  Growth by infiltration :-Invasion may be due to-

  a) *Rapid multiplication-*

  b) *Motility* –mesenchymal origin cells are actively amoeboid

  eg. Fibroblasts, R.E.cells, meningothelial cells, hemopoietic cells

  C*) Metabolites-*

  d) *Enzymes* – hyaluronidase enzymes hydrolyses the intercellular cement substances.

  -Proteases--

NEOPLASIA

- **Routes of invasion –**

3. **Blood spread**- entry into blood vessels thr'-

a) via thorasic duct-

b) infiltration into vessels-

Portal veins – metastases into liver.

Systemic veins- metastases into lung.

4. **Transcoelomic spread-**

Spread of tumor cells in the body cavities is known as *transcoelomic spread*.

NEOPLASIA

- **Routes of invasion** –

5. Implantation –

a) By natural passages- tumor cells growing lining surface of hollow organs cast of in the lumen. Or spread of cells from abdominal tumor to other organs.

b) Inoculation- surgical implant.

c) Coitus – TVG.

6. **Spread by nerves –**

along the perinural lymphatics

Lymphatic metastasis

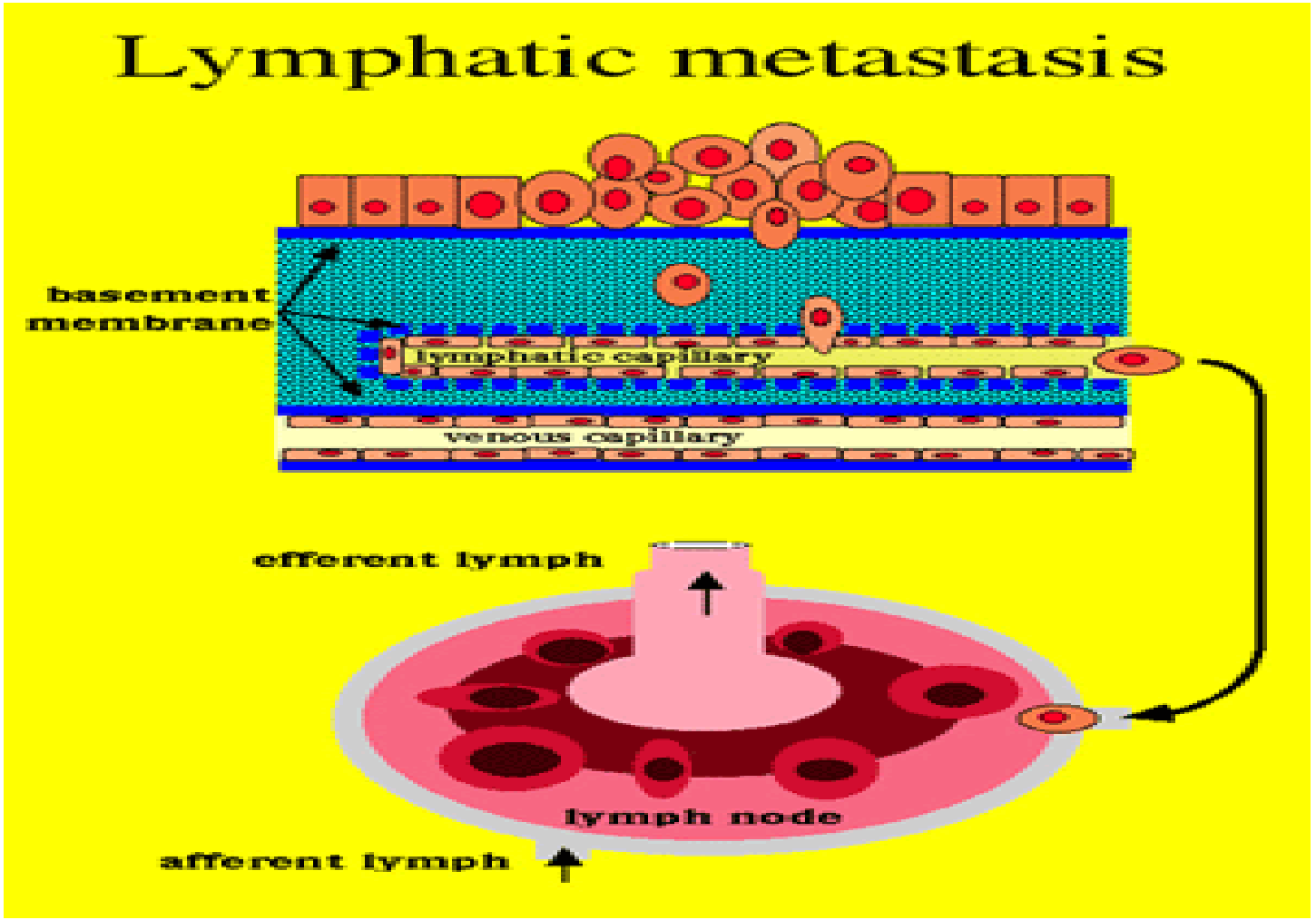

Haematogenic metastasis

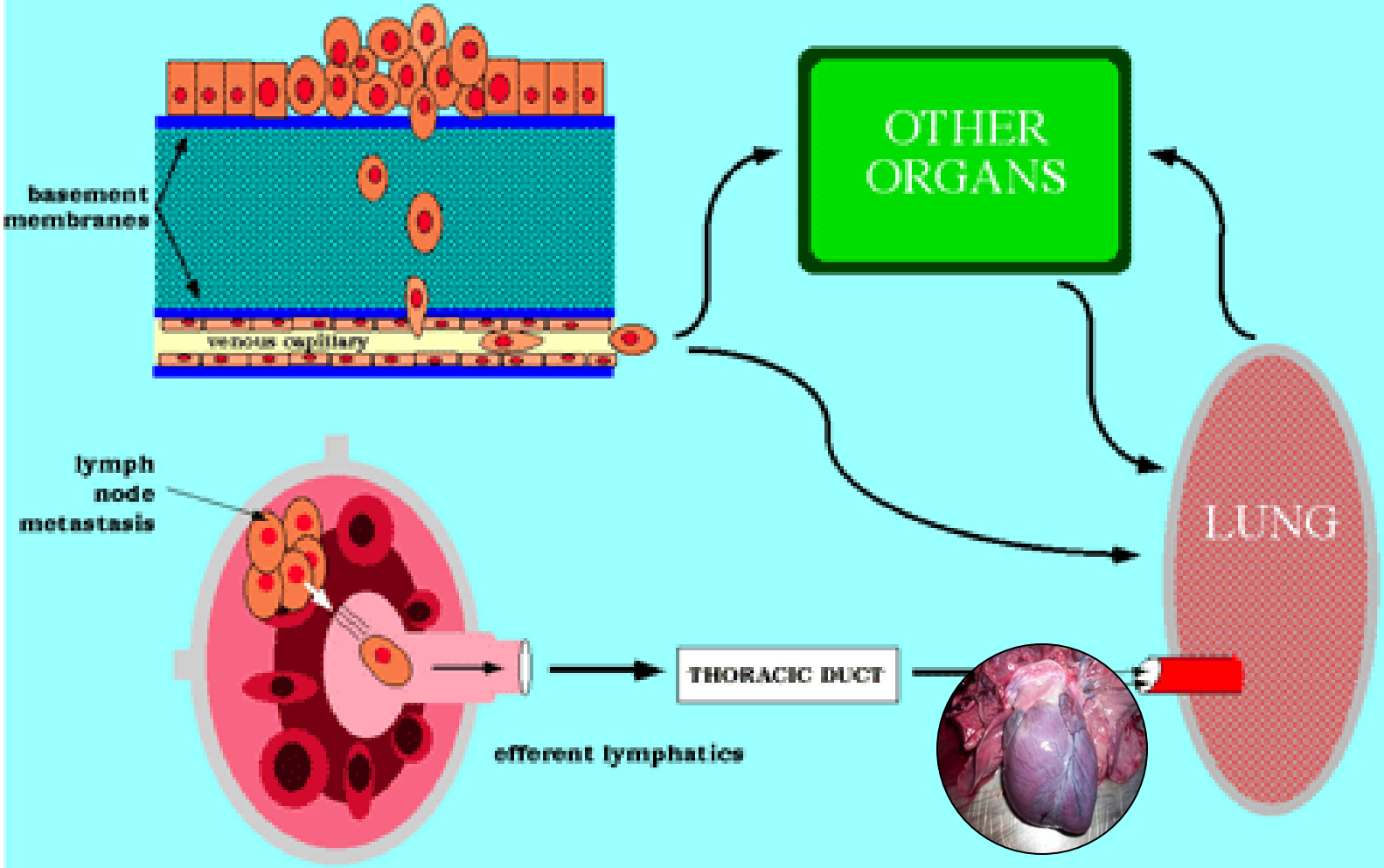

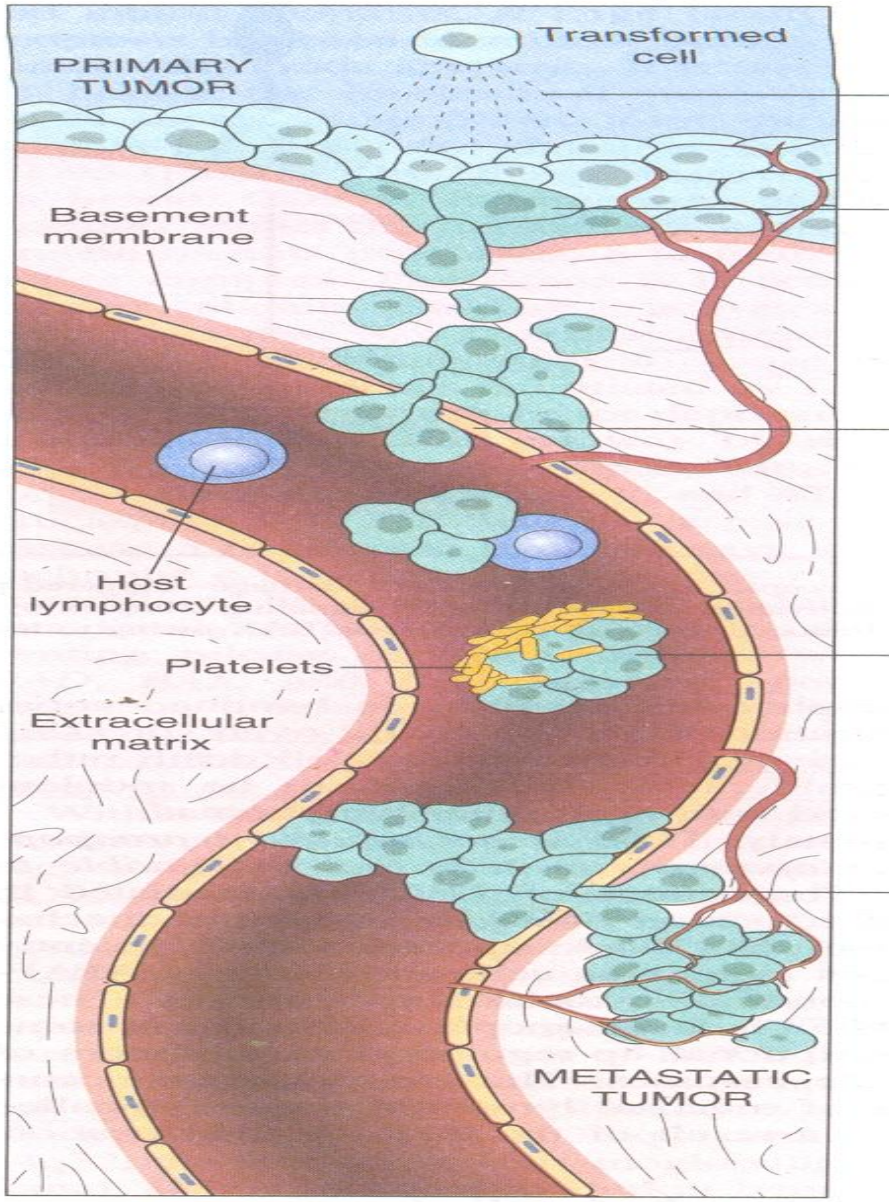

Vascular Dissemination

- **Penetration**
- **Embolization**
- **Tumor cell arrest**
- **Adhesion**
- **Extravasation into organ parenchyma**

Nitric oxide and Hematogenous route

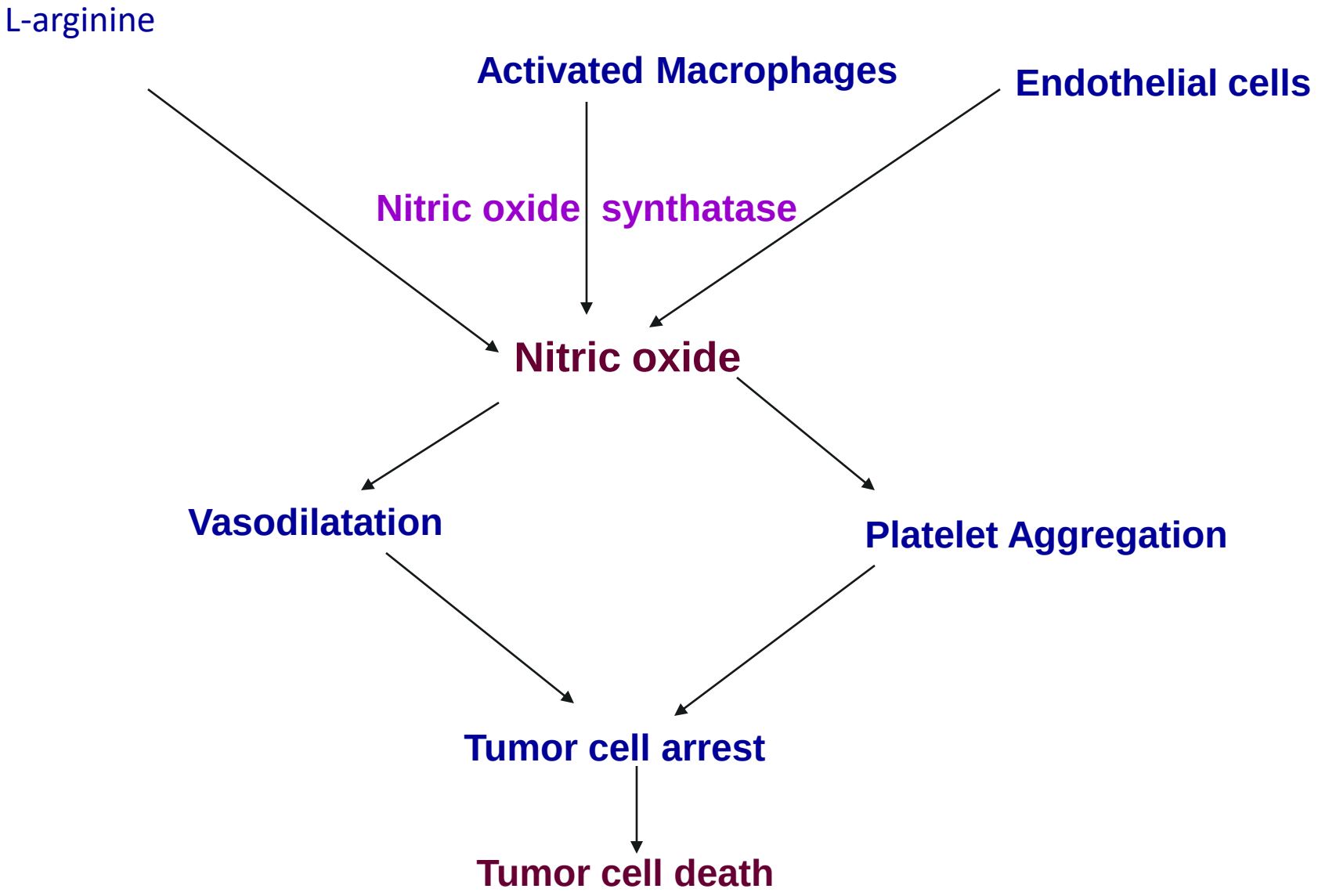

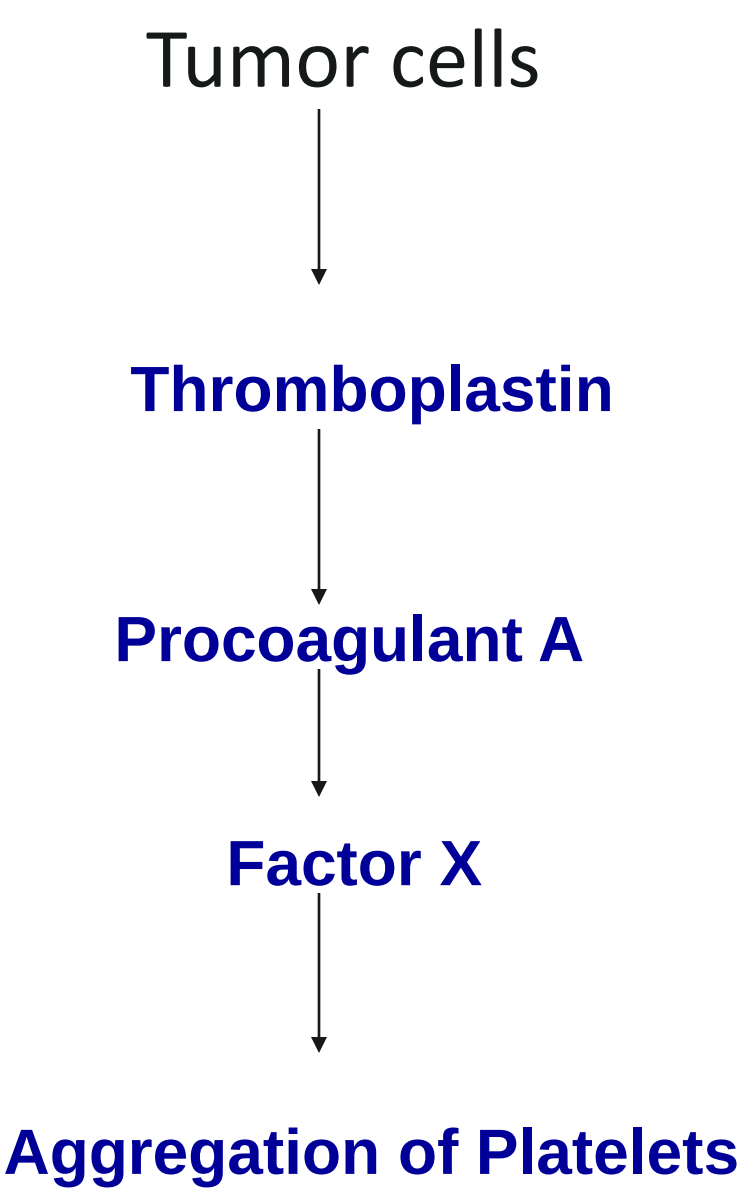
Tumor cells
Thromboplastin
Procoagulant A
Factor X
Aggregation of Platelets

Invasion of extra cellular matrix

- Detachment from adjacent cells
- Attachment to matrix components
- Degradation of extra cellular matrix
- Migration of tumor cells

Detachment from each other

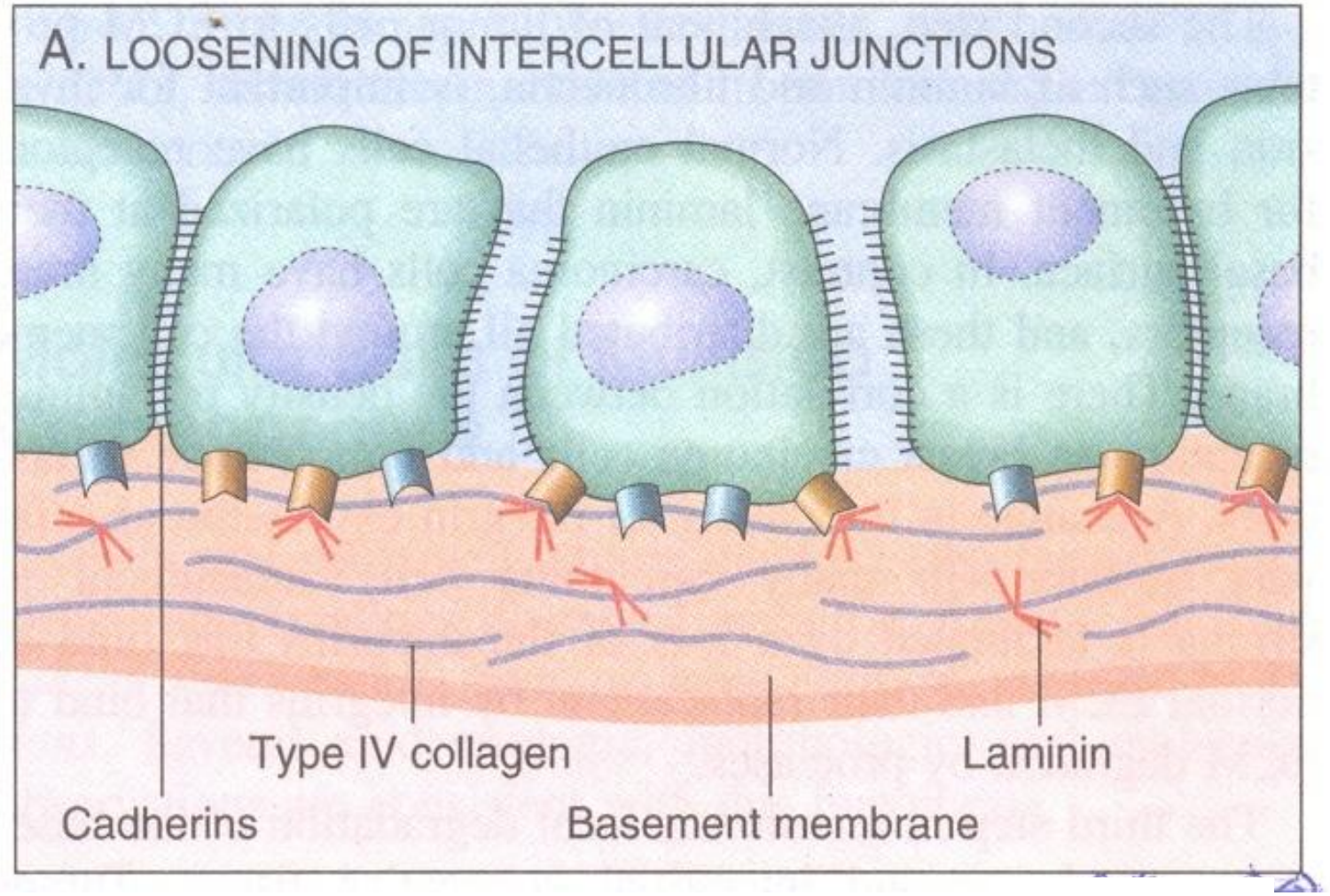

Attachment to matrix components

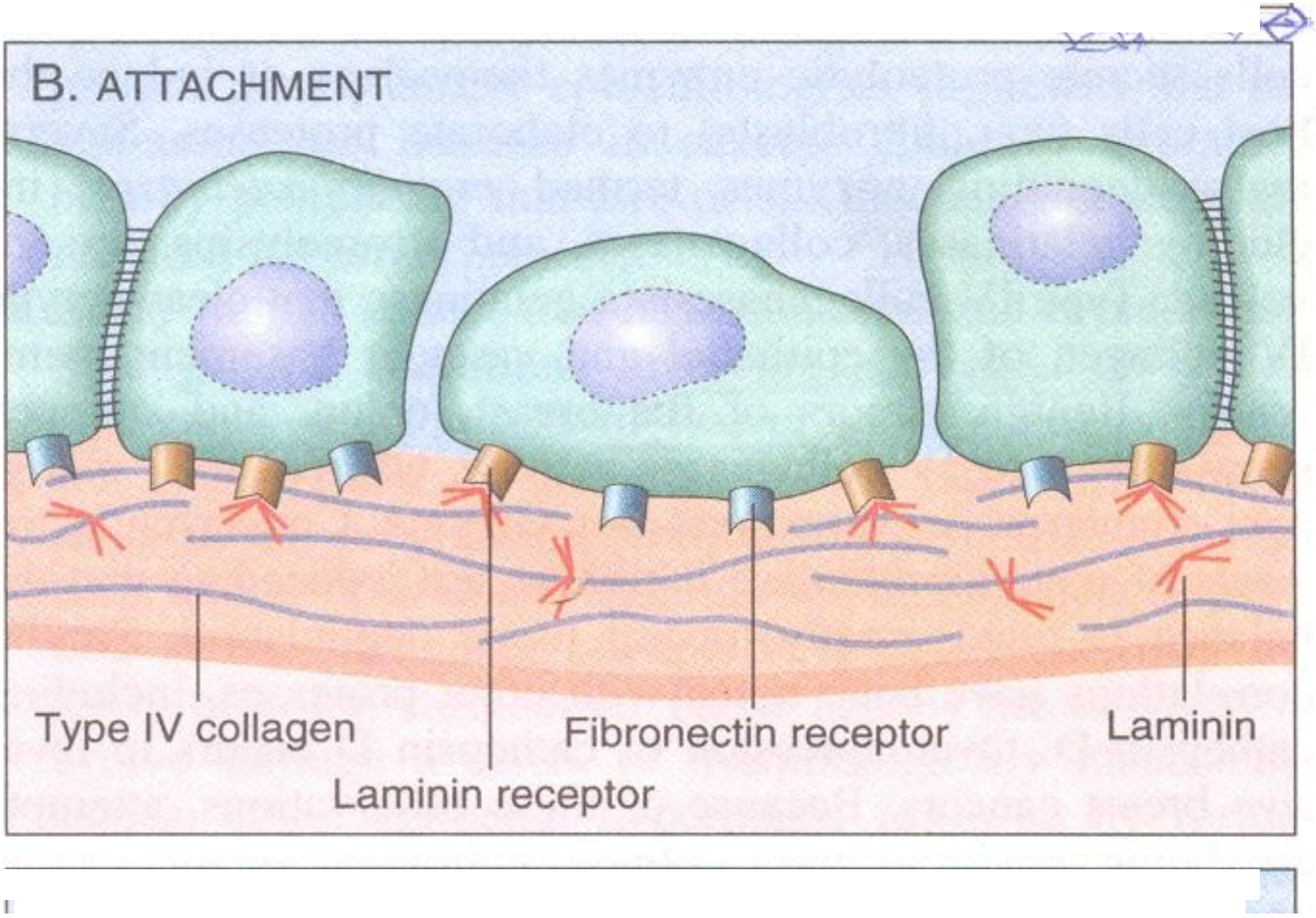

Degradation of extra cellular matrix

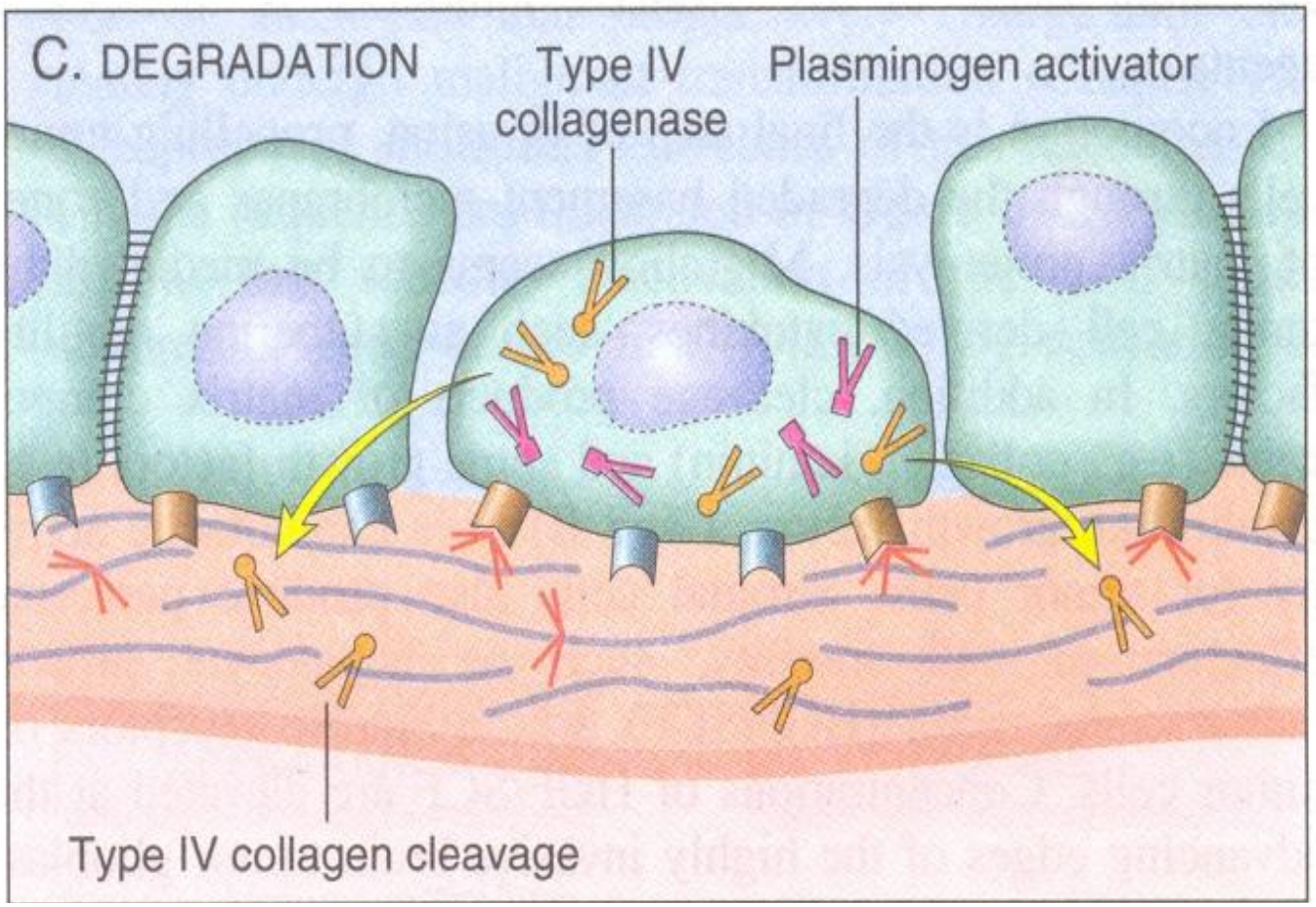

Migration of tumor cells

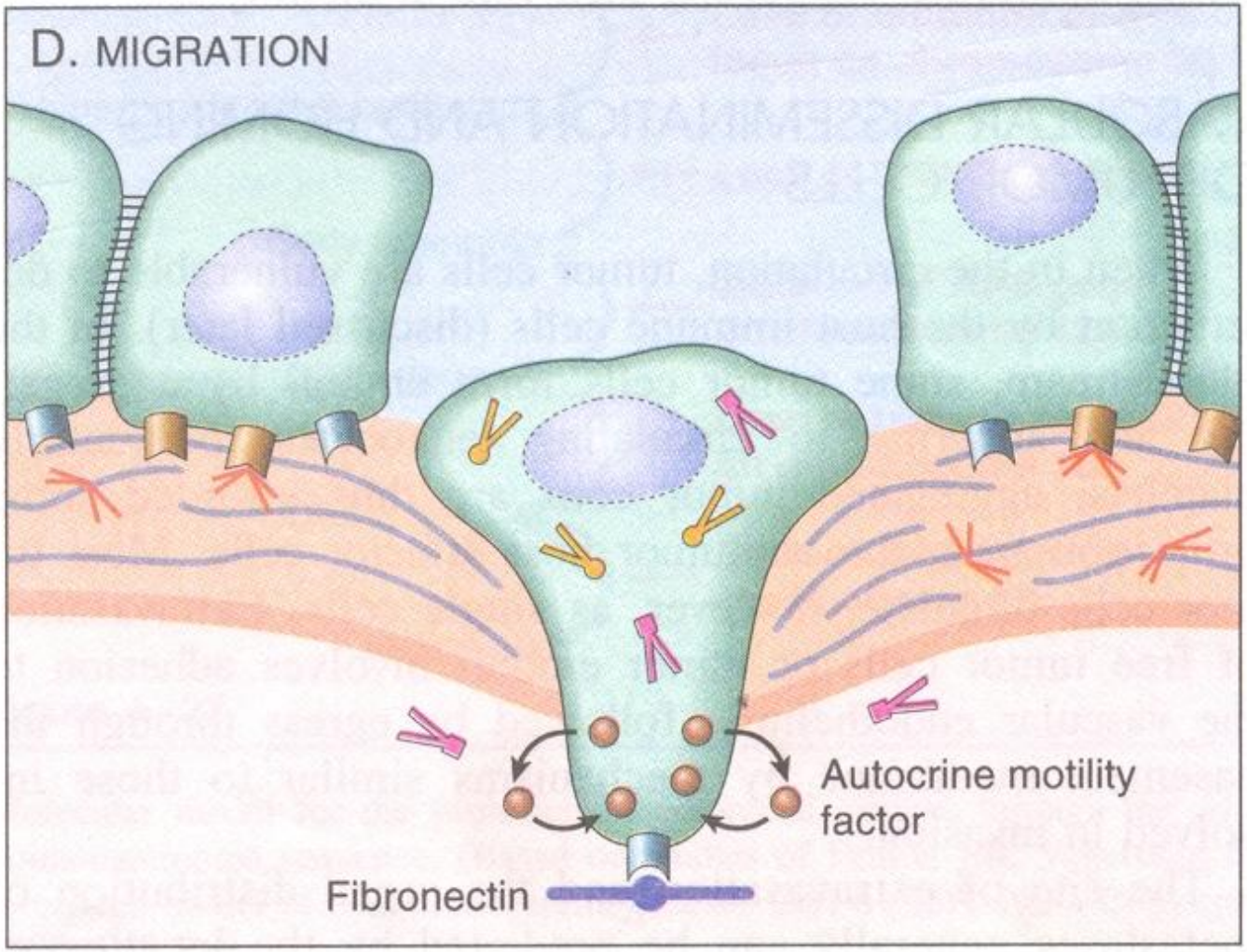

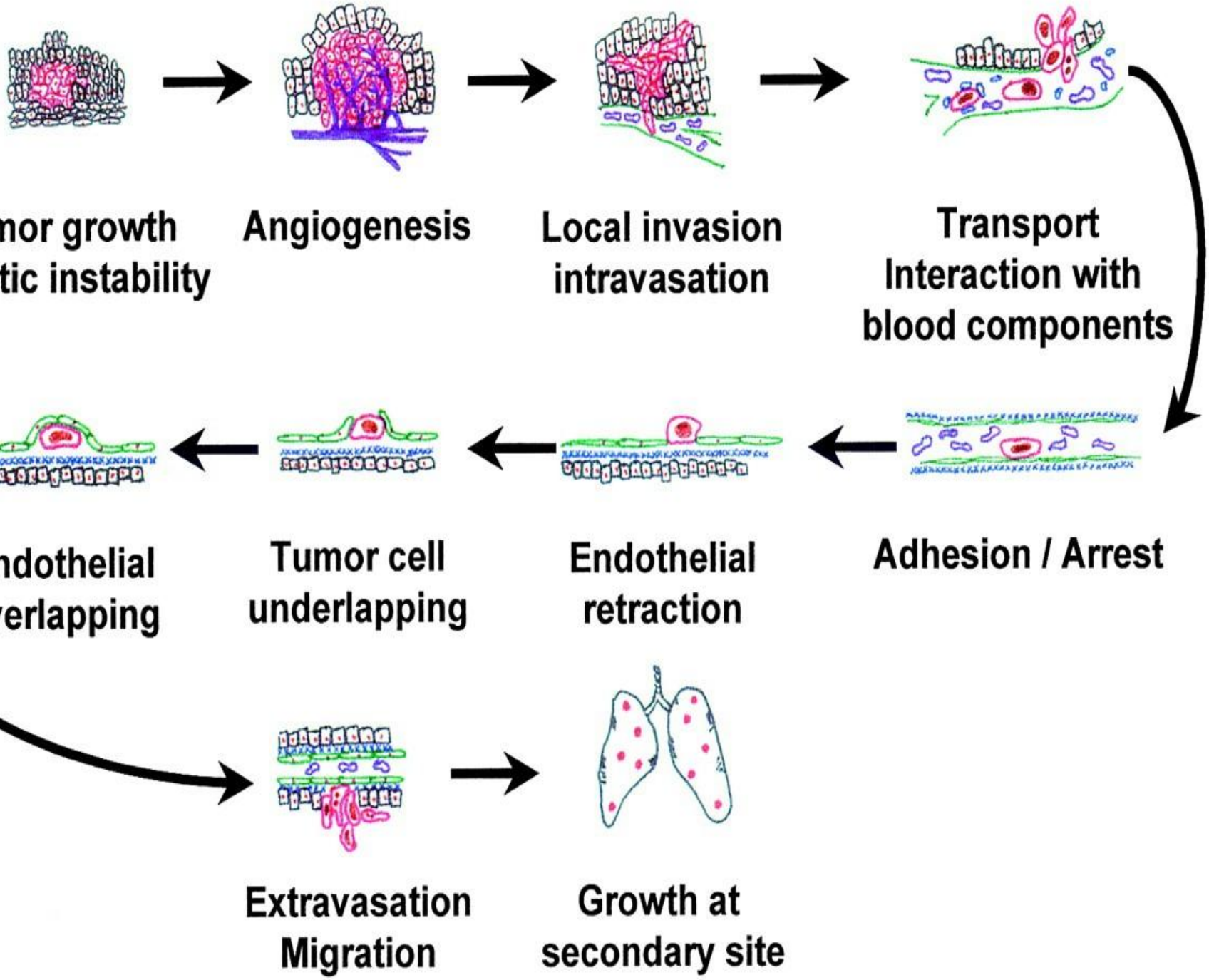
Tumor growth
Genetic instability
Angiogenesis
Local invasion
intravasation
Transport
Interaction with
blood components
Adhesion / Arrest
Endothelial
retraction
Tumor cell
underlapping
Endothelial
overlapping
Extravasation
Migration
Growth at
secondary site

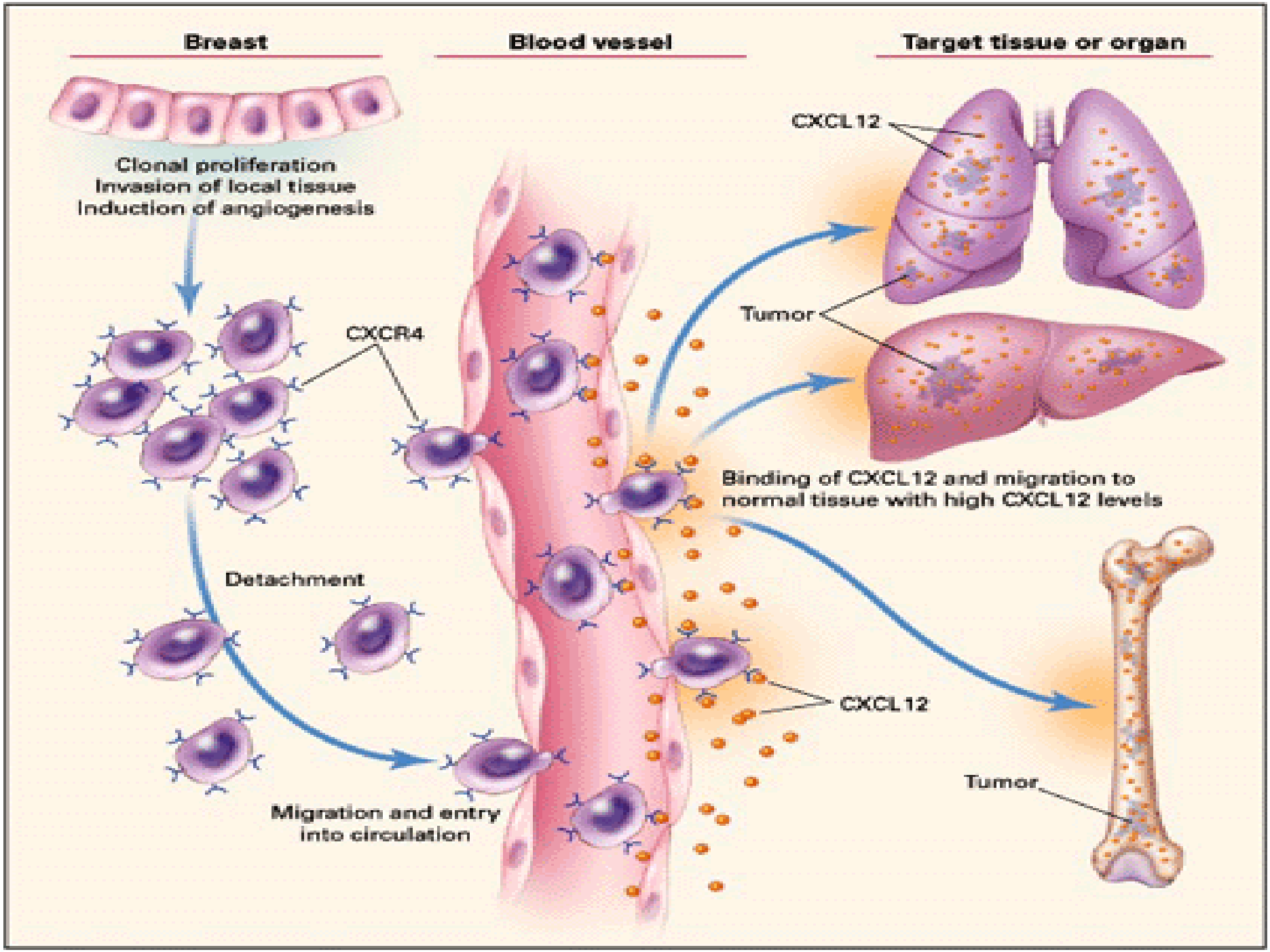
Breast
Blood vessel
Target tissue or organ
Clonal proliferation
Invasion of local tissue
Induction of angiogenesis
CXCR4
Detachment
Migration and entry
into circulation
CXCL12
Tumor
Tumor
Binding of CXCL12 and migration to
normal tissue with high CXCL12 levels
CXCL12
Tumor

Metastatic chondrosarcoma. (Primary tumor on the rib) **Lt lung in lateral view w/ many white nodules**

Coronal section of brain with military dark red foci

Metastatic hemangiosarcoma

Metastatic neoplasia.
Histiocytic sarcoma in liver

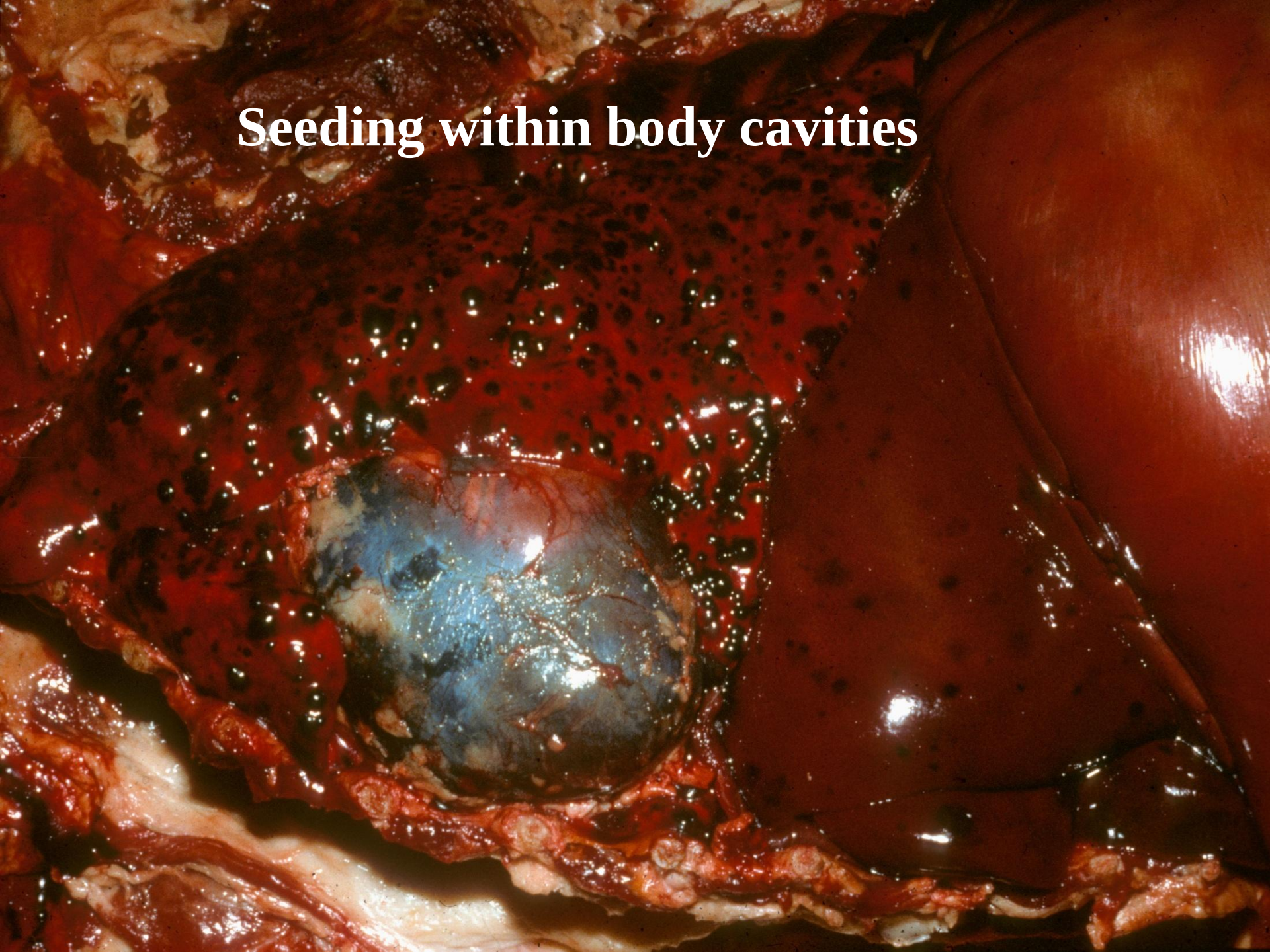
Seeding within body cavities

Angiogenesis

Growth Factors

1. VEGF 2. b-FGF 3. Angiogenin

4. PDGF 5.Angiotropin 6.TNF-α,IL-1

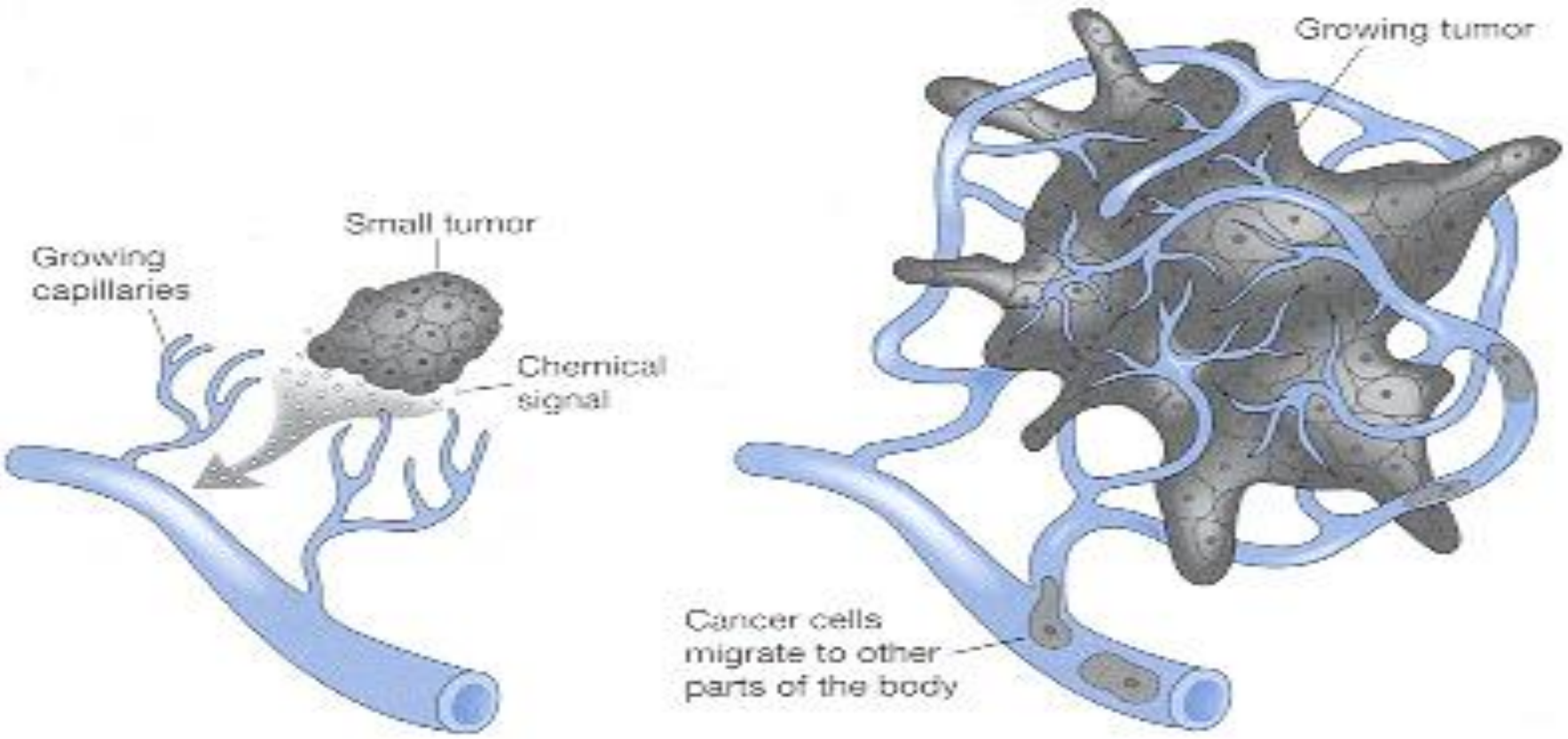

Angiogenesis and its inhibition

Normal	In cancer
TP 53 Gene ↓ Thrombospondin -1 ↓ Angiogenesis inhibitors	Mutation in TP 53 Gene ↓ Decrease levels of Thrombospondin -1 ↓ Angiogenesis promotion

Anti Angiogenic factors

Imbalance of angiogenic
and antiangiogenic factors :

1. **Thrombospondin - I**
2. **Angiostatin**
3. **Endostatin**
4. **Vasculostatin**

Lung with Metastatic Thyroid Carcinoma

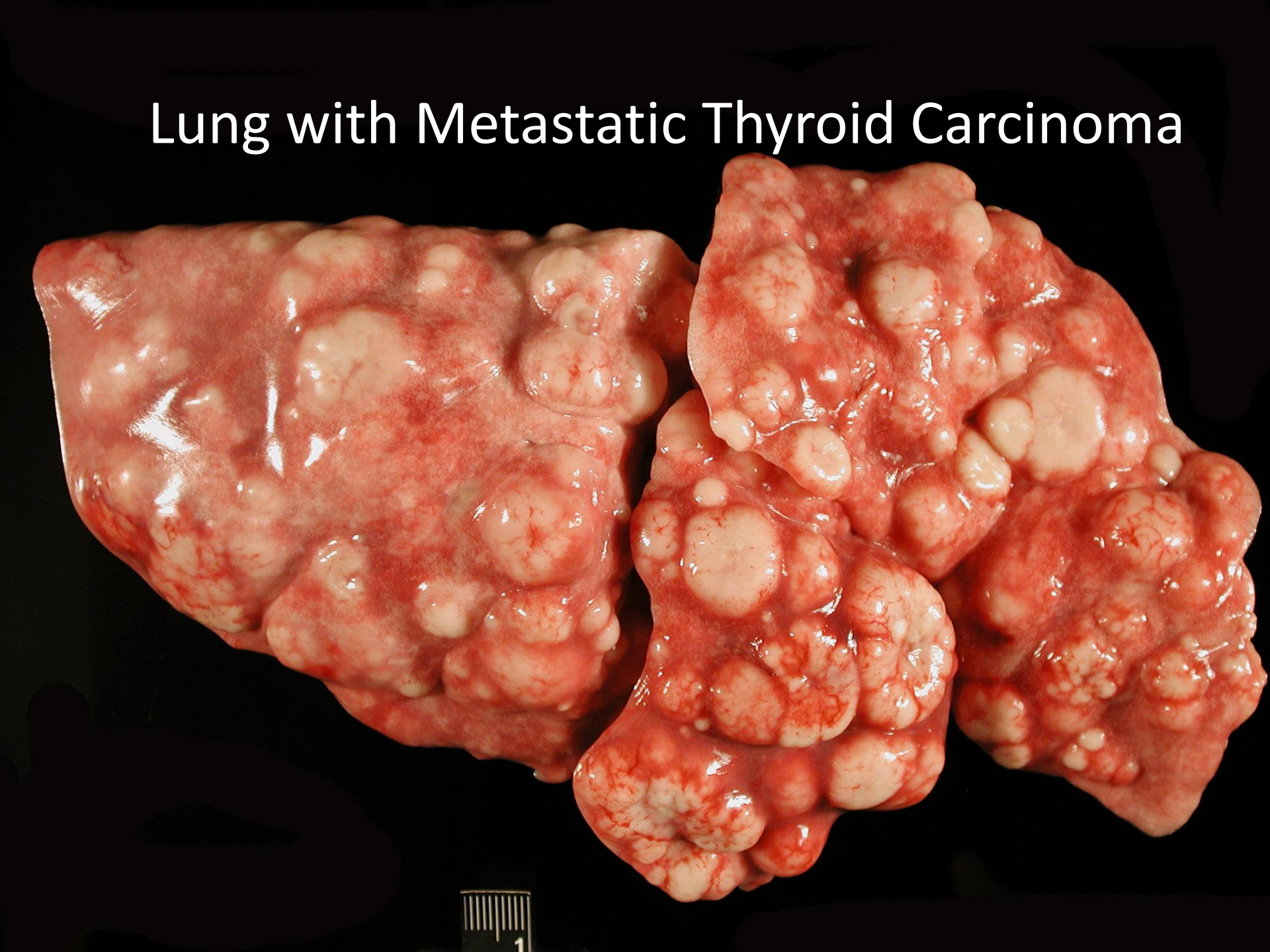

Humerus : Metastatic carcinoma

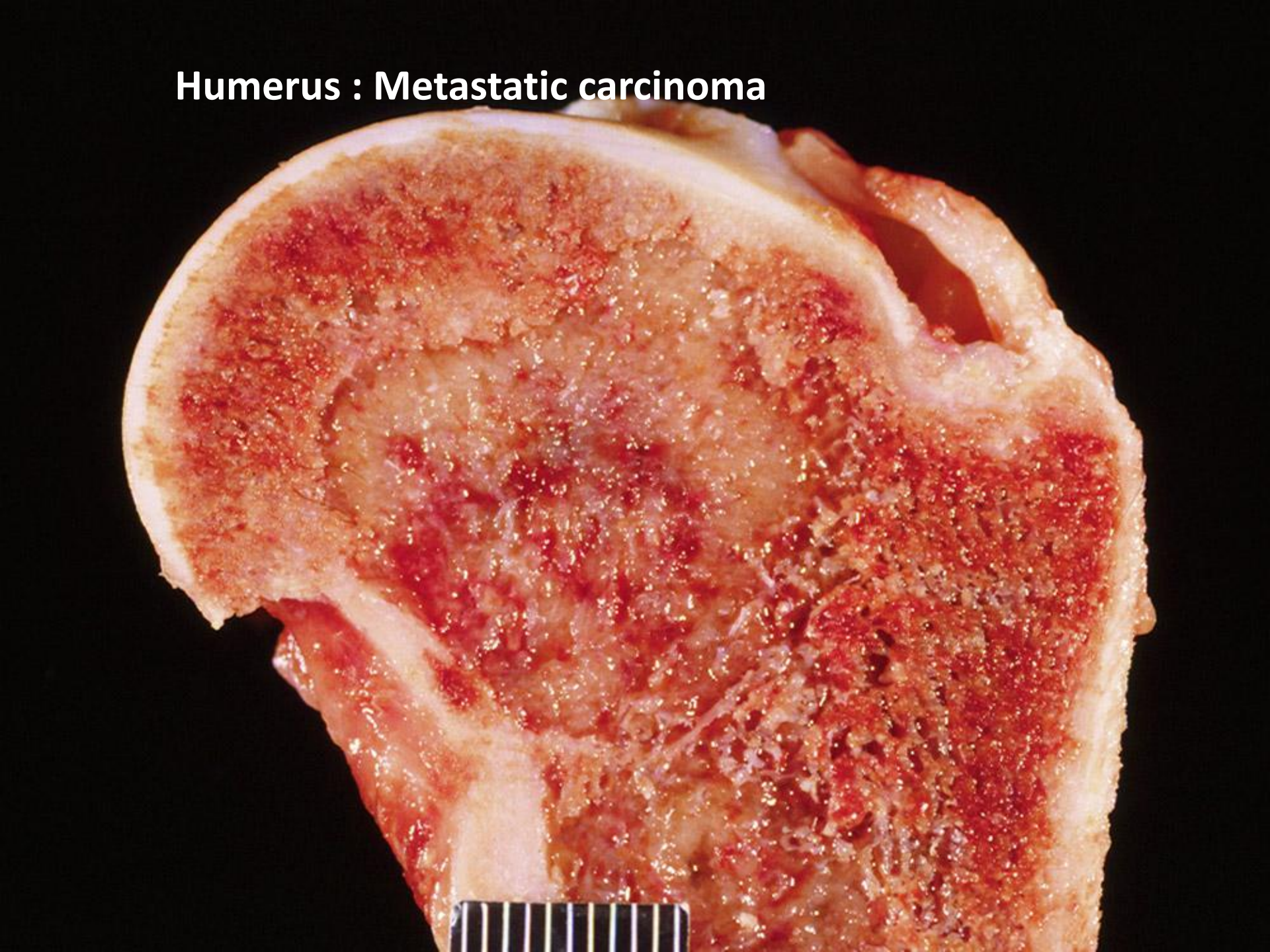

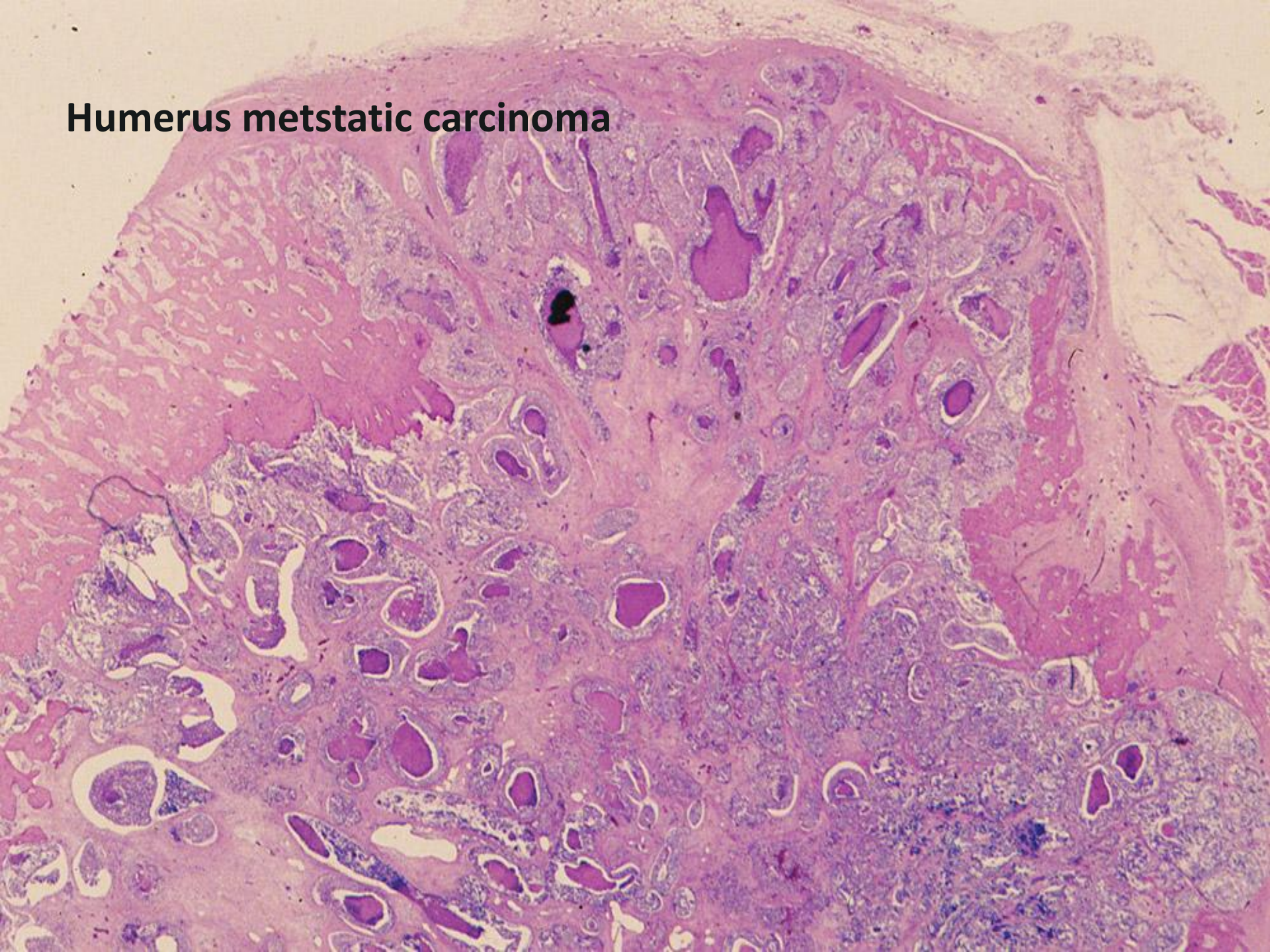
Humerus metstatic carcinoma

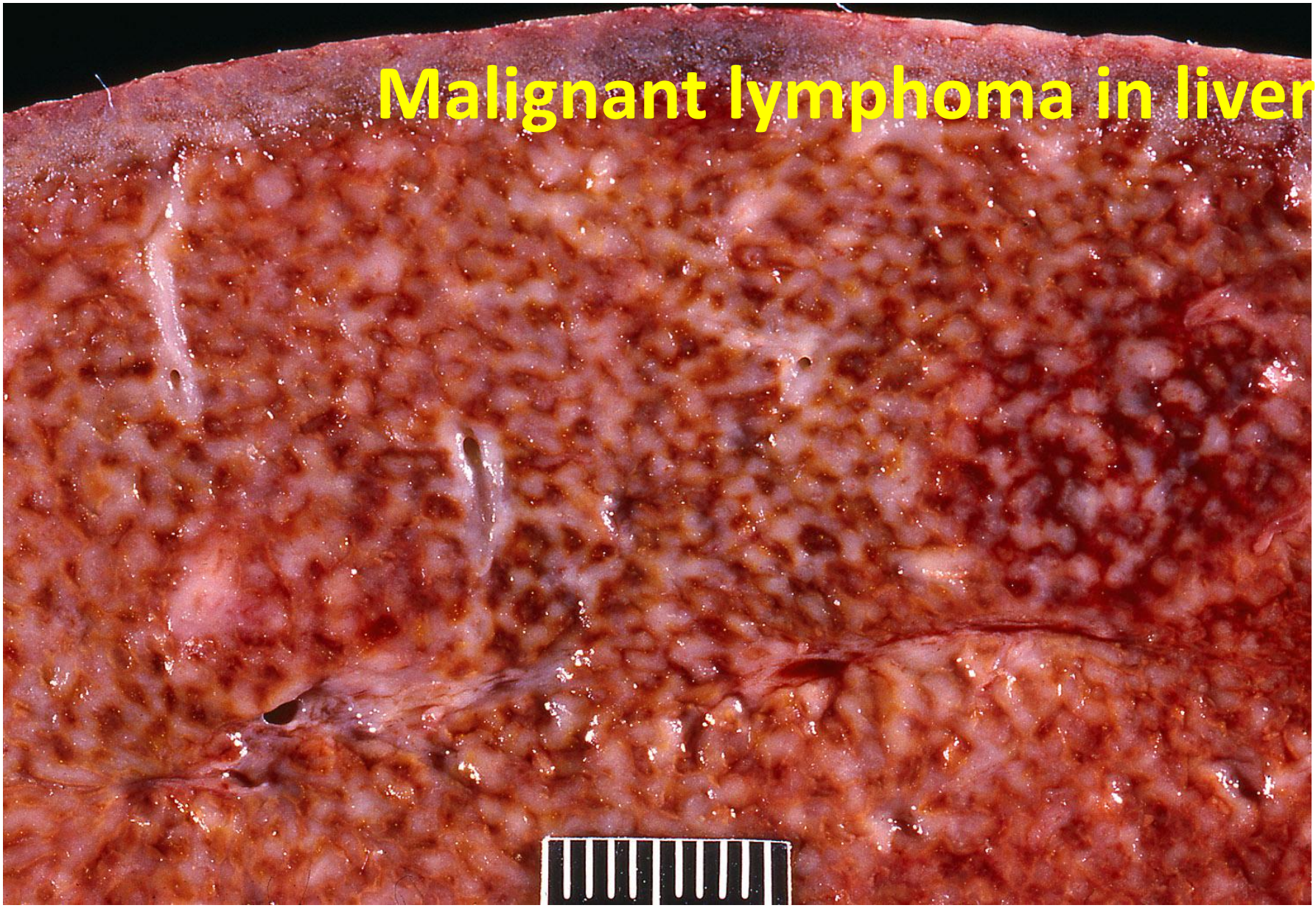
Malignant lymphoma in liver

Kidney with multiple large white nodules Malignant

lymphoma

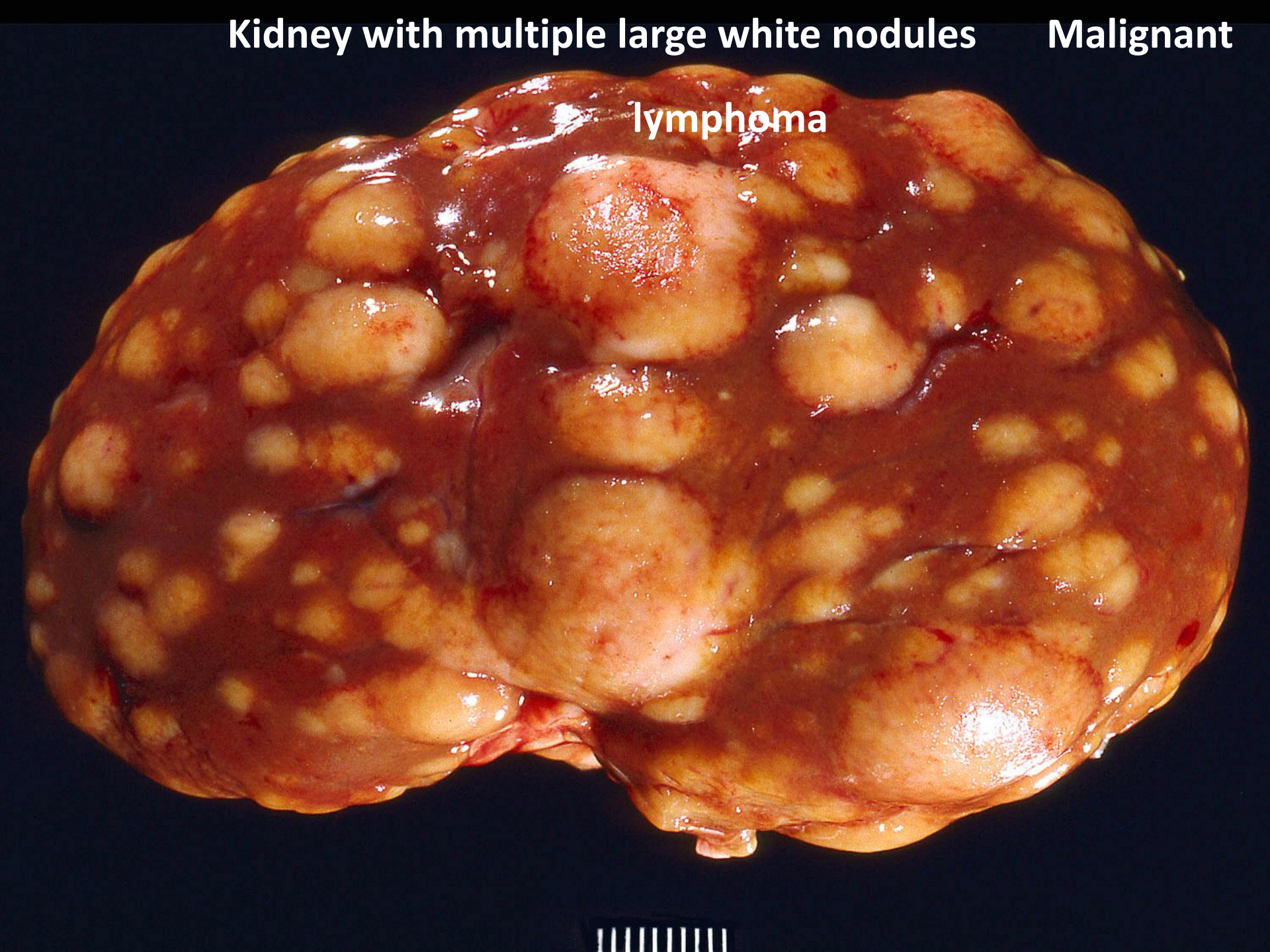

Bronchopneumonia with Metastatic nodules

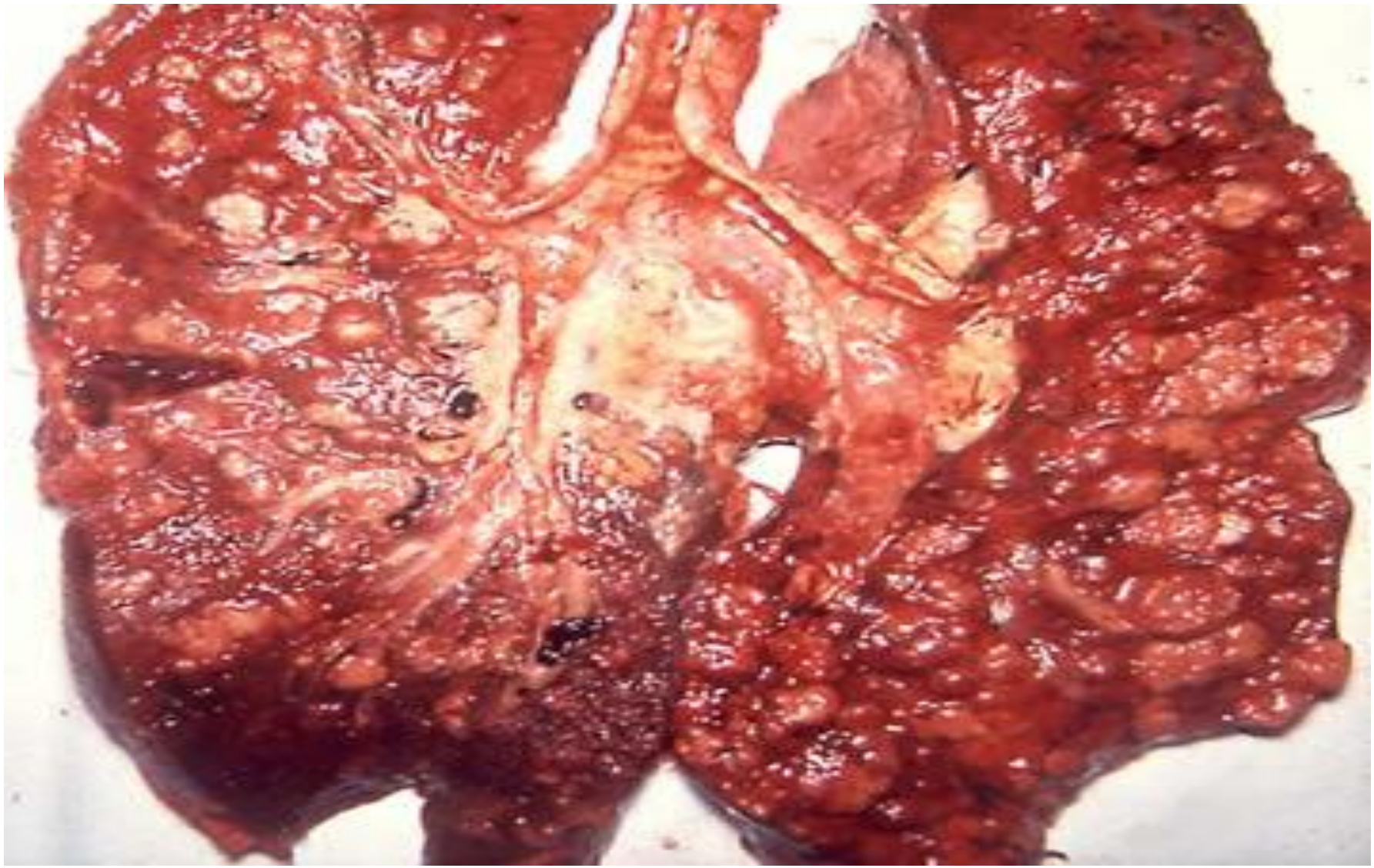

Adenocarcinoma metastasis to liver

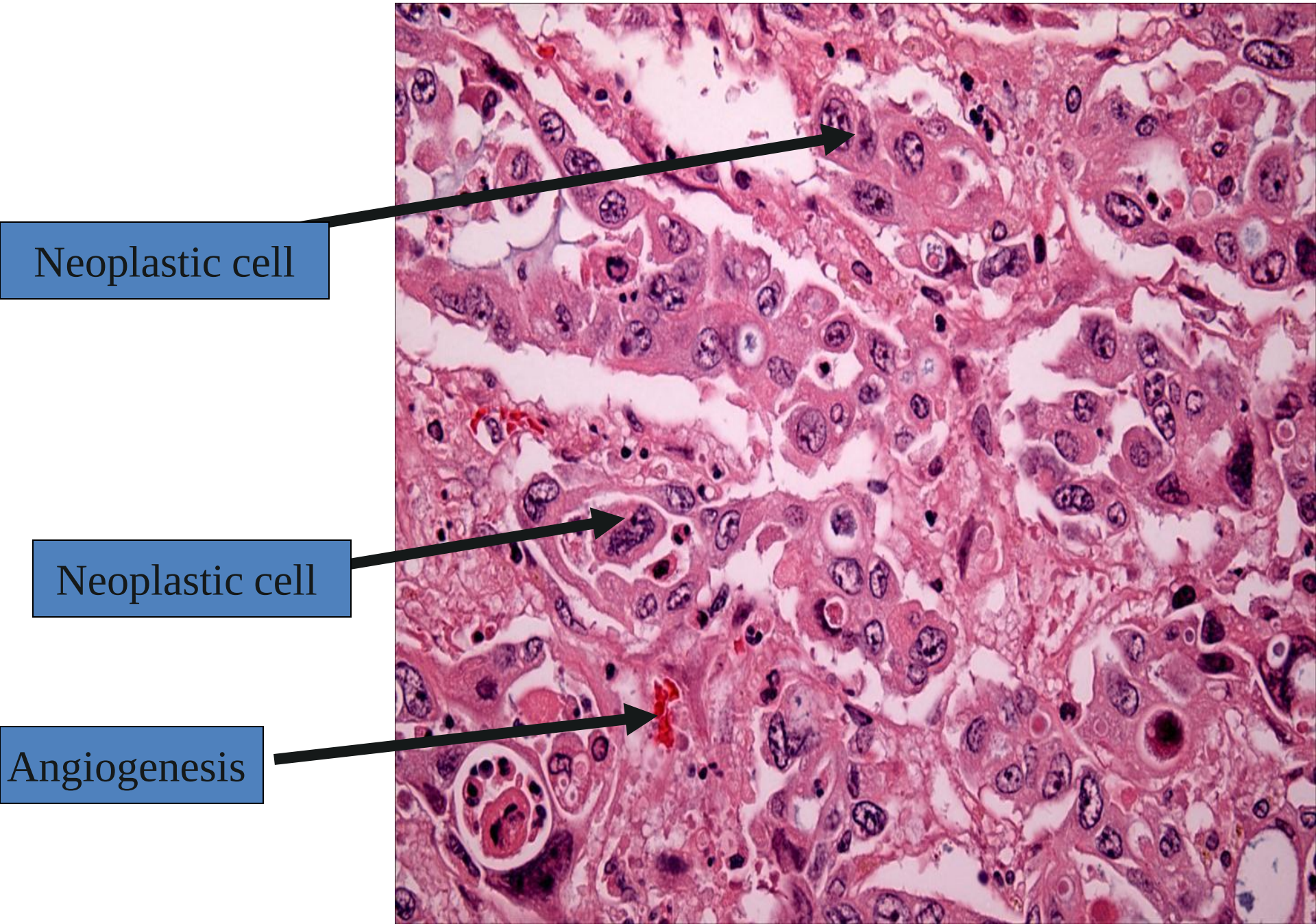

Lymph node biopsy

Morphology, Anaplasia and many mitotic figures
Suggest High grade squamous cell carcinoma

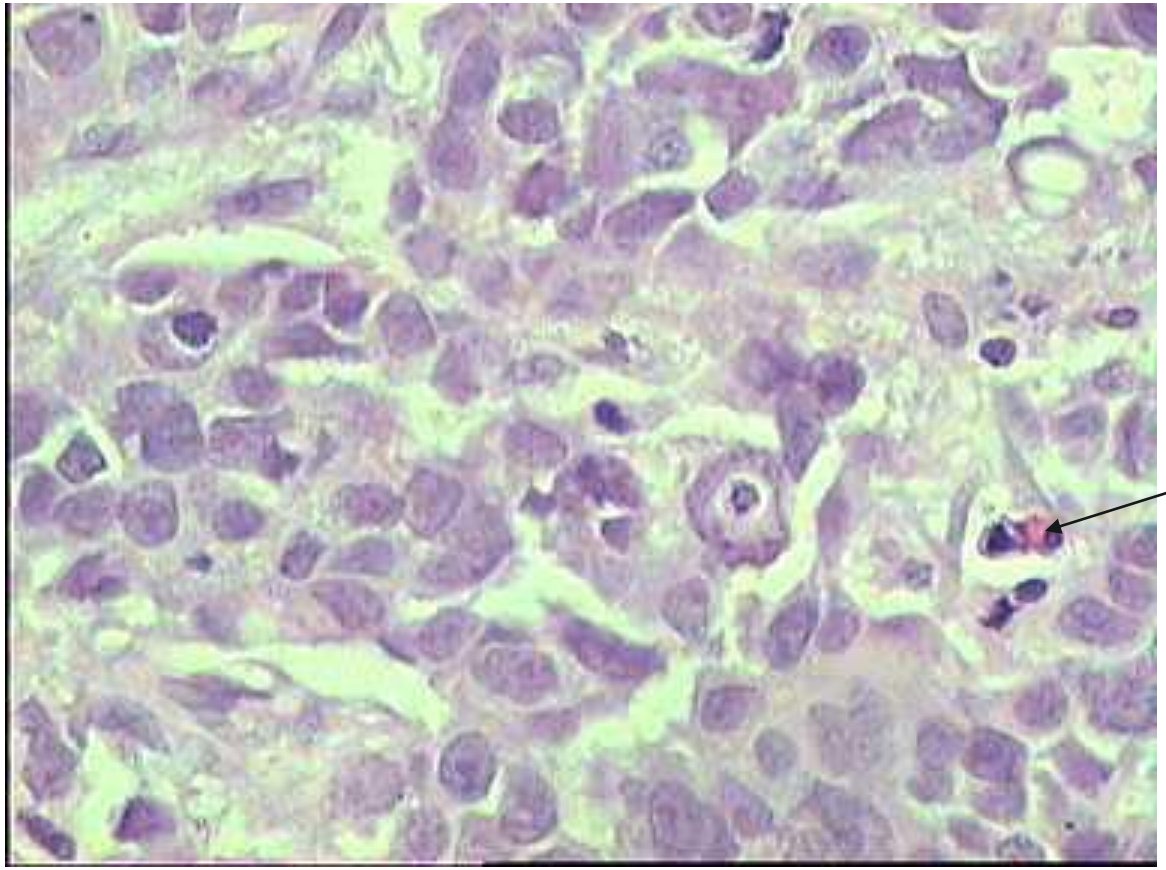

Tumor Blood vessel (angiogenesis)

Mitotic figures

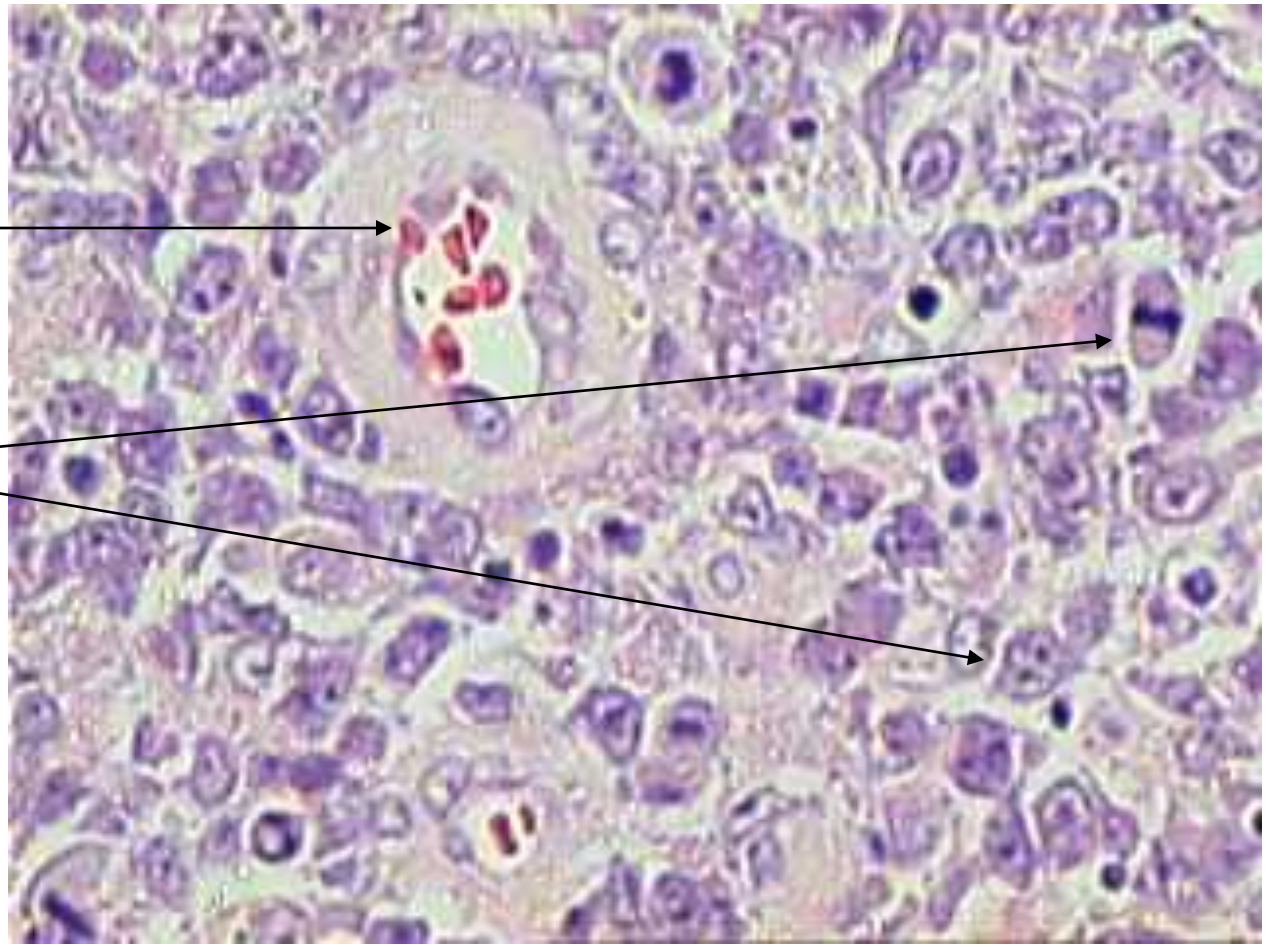

Metastatic thyroid carcinoma in lymph node

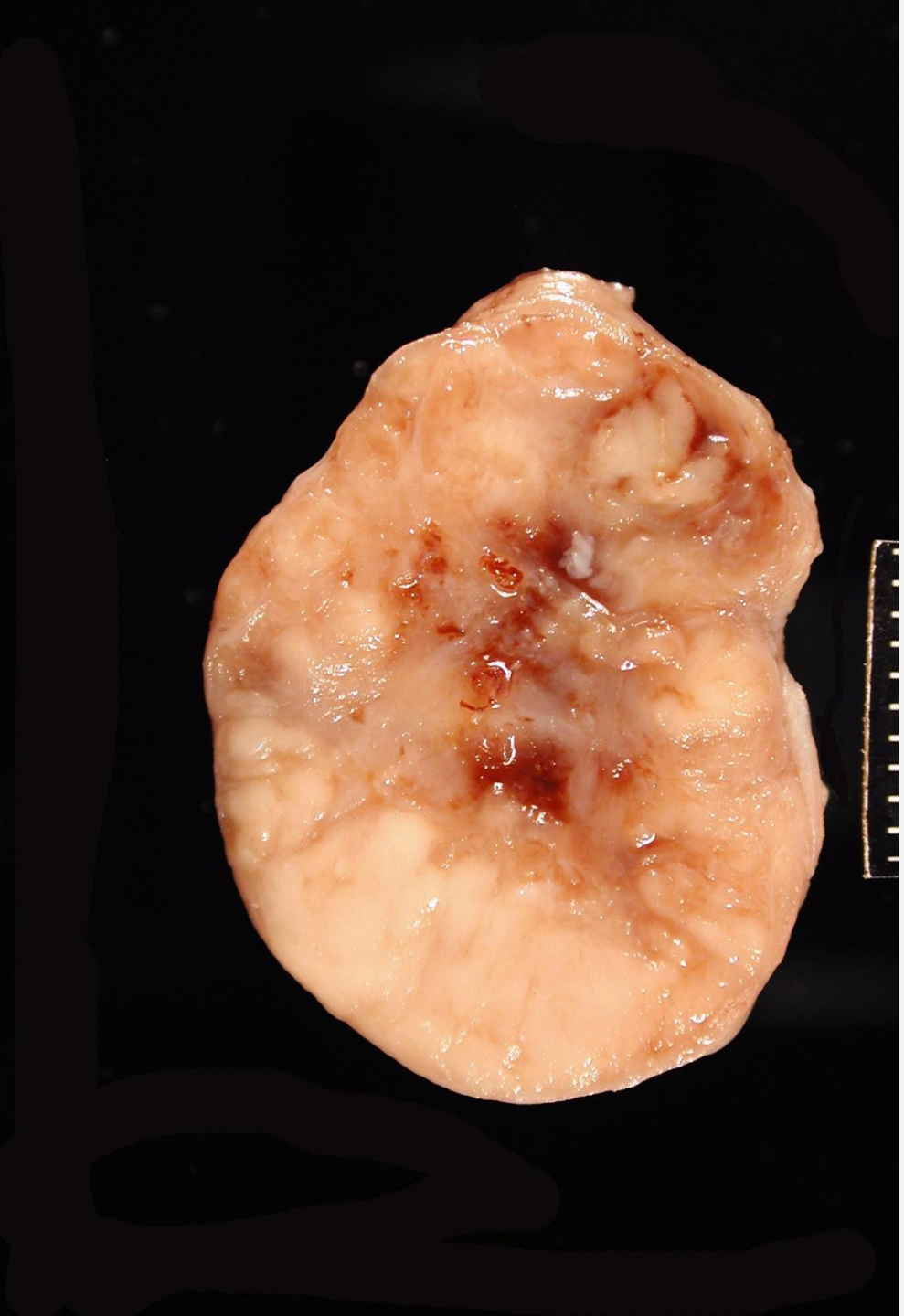

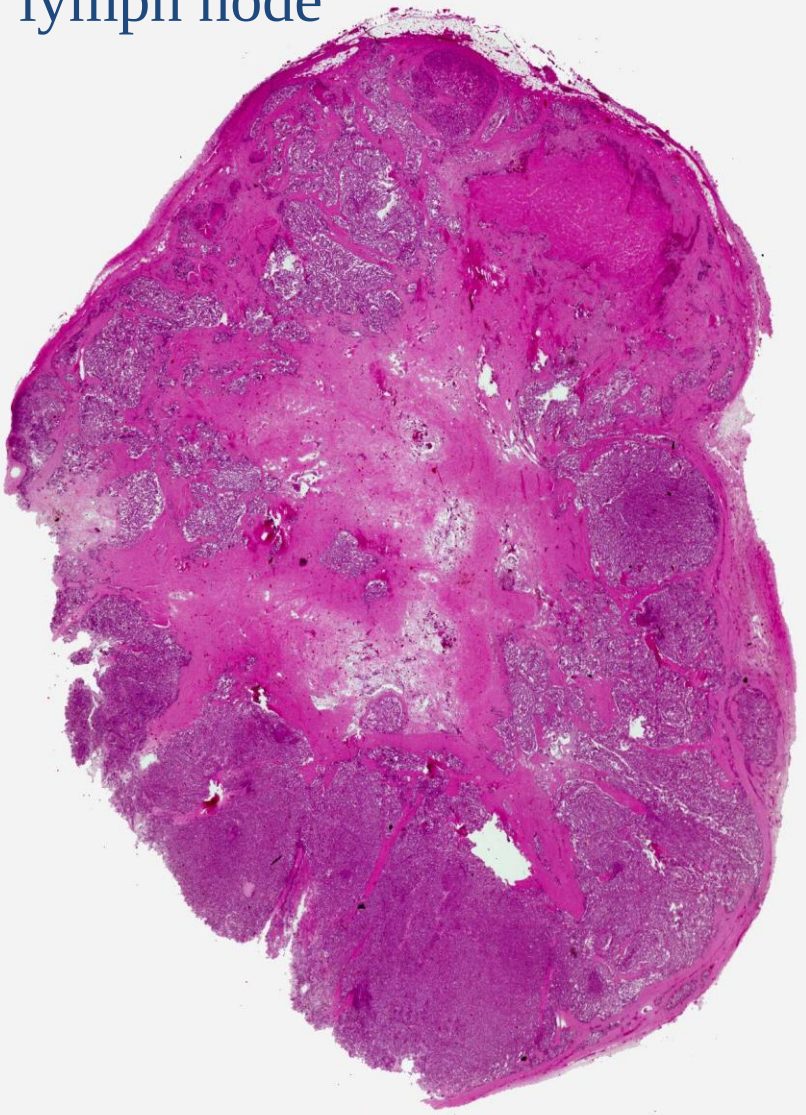

❖Diagnosis

- ✓Health status
- ✓Radiology
- ✓Sonography
- ✓Computerized Tomography Scans
- ✓Magnetic Resonance Imaging
- ✓Scintigraphy
- ✓Tumor markers
- ✓FNAB
- ✓Tissue Biopsy AND Histopathology